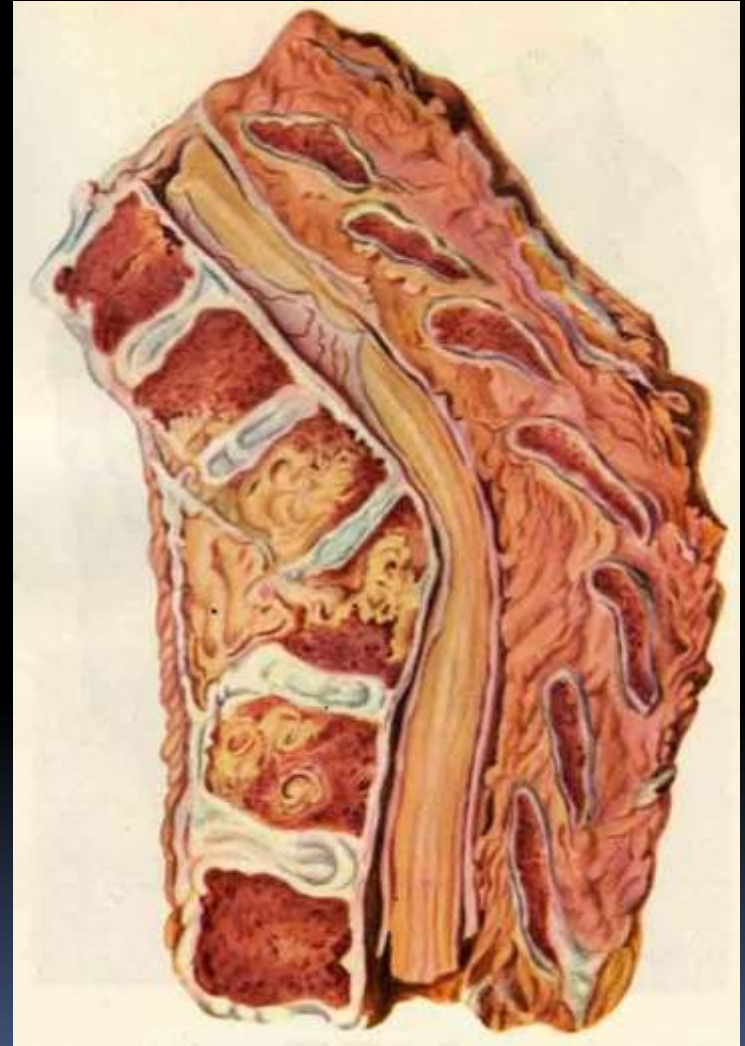
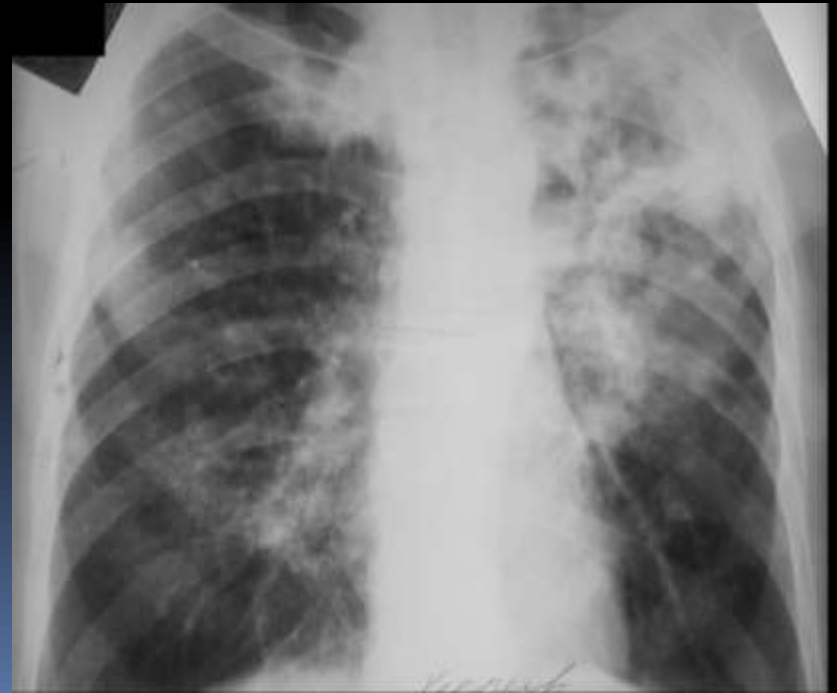
TUBERCULOSIS OF BONES AND JOINTS



ethyology

- Caused by *Mycobacterium tuberculosis*, tuberculosis most commonly affects the lungs, lymph nodes and serous membranes, the bones and joints being the last to be involved with the incidence as low as about 10%.



localization

- The major sites of osseous and articular tuberculous lesions include the epiphyses of the long bone shafts, bodies of the short bones: f.e. vertebrae and diaphyses of the digital phalanges.
- Analogically, this type of tuberculosis falls into the major forms:
 - •tuberculous spondylitis, or spinal TB (40%);
 - •tuberculous coxitis, or hip joint TB (20%);
 - •tuberculous gonitis, or knee joint TB (15- 20%)

Specific inflammatory reaction

- Tuberculosis of the bone and joints is usually due to a secondary TB infection, which implies its lymphohaematogenous spread from the primary pulmonary focus or that of other organs.
- Mycobacterium induce specific inflammatory reaction within the bone marrow of epiphyses, the site known to have a slower blood flow.
- This results in primary osteitis of tuberculous osteomyelitis.

caseous necrosis

- The initial tuberculous focus undergoes caseous («cheese-like») necrosis around which further tubercles form to merge with the initial focus.
- Subsequently, granulation occurs which, in turn, is subject to necrosis.
- This leads to sequestration: the bony tissues involved in the necrosis become completely separated from the underlying bone.

TB synovitis

- The progression of tuberculous inflammation into the joint forms an articular sac with subsequent caseous necrosis of the joint cartilage and contiguous osseous tissues.
- Primary synovial tuberculosis (TB synovitis) only occurs in about 5% of cases, with a favourable outcome as it is unlikely to cause the damage to the joint ends of the bones.

pathogenesis of tuberculosis of the bone and joints

- involves the three stages:
- stage 1 – prearthritits- formation of the bone focus in the epiphysis around the joint;
- stage 2 - arthritits - extension of the process to the joint with resultant secondary arthritits;
- stage 3 - post-arthritits- stabilization of the disease with the evidence of its complications.

clinical picture:

1. Complaints

- loss of appetite;
- easy fatigability;
- difficult walking;
- weight loss;
- low grade fever.

2. History of present illness

- impaired limb function followed by pain on moving (most often in the back, hip and knee joints) which, as a rule, worsens on walking and bending


3. Family and past medical history

- evidence of tuberculosis in the family (e.g, parents);
- contacts with contagious tuberculosis cases
- provoking factors (e.g. trauma);
- history of an infection.

4. Physical examination

- weight loss;
- muscle atrophy at the limb affected;
- skin and mucosal pallor.

X-ray of bones (to detect changes in the spongy bone tissues at metaphyses):

- osteoporosis;
- foci of sequestration coupled with clear areas in the form of a soft shadow («a piece of melting sugar» sign); 
- widening of the joint space followed by its narrowing;
- notching of joint cartilaginous and osseous tissues;
- osteosclerosis and periostitis are usually absent.

Different diagnostic

- It is noteworthy that tuberculosis of the bones has to be differentiated from chronic haematogenous osteomyelitis

Treatment

- Involves both conservative and surgical methods.
- Antibacterial chemotherapy requires the use of specific antituberculous antibiotics
- Affected organ must be immobilized , which prevents bone deformation and favours healing.
- Splints, jackets and dressings are applied

Surgery –

Is one of the major modalities in complex management

- Radical operations:
- Necrectomy, or excision of periarticular tuberculous foci from the vertebral bodies and the bone epiphyses;
- Bone resection, or removal of the joint ends of bones destructed

Ancillary operation:

- Arthrodesis (i.e. forming artificial ankylosis), or the immobilization of the joint, especially in the case of tuberculous spondylitis (spondylodesis) when the vertebral column is fixed using bone transplantants or metallic constructions
- Laminectomy is indicated in compression of the spinal cord

Reconstructive operation:

- Osteotomy and joint trepanation to restore the organ's (limb, joint, spine) function after the inflammation has been eliminated





